

## Radiosurgery of Spinal Meningiomas and Schwannomas

www.tcrt.org

Purpose of this study is to analyze local control, clinical symptoms and toxicity after image-guided radiosurgery of spinal meningiomas and schwannomas. Standard treatment of benign spinal lesions is microsurgical resection. While a few publications have reported about radiosurgery for benign spinal lesions, this is the first study analyzing the outcome of robotic radiosurgery for benign spinal tumors, treated exclusively with a non-invasive, fiducial free, single-fraction setup. Thirty-six patients with spinal meningiomas or schwannomas were treated, utilizing a robotic radiosurgery system (CyberKnife®, Accuray Inc. Sunnyvale CA), and were followed prospectively. Medical history, histology, clinical symptoms and radiographic outcome were recorded. Thirty-nine spinal lesions were treated because of tumor recurrence, remnants after microsurgery, multiple lesions, or rejection of open surgery. Median age was 45 years (range 18-80 years). Median target volume was 3.4 cm<sup>3</sup> (range 0.2-43.4 cm<sup>3</sup>). Histology revealed 28 schwannomas and 11 meningiomas (WHO grade I). All spinal levels were affected. Median prescription dose was 14 Gray (95% C.I. 13.4-14 Gy) to the 70% isodose. After a median follow-up of 18 months (range 6-50 months) no local tumor progression was detected. 20 lesions (51%) remained stable, 19 tumors (49%) decreased in size. One patient with schwannomatosis was treated repeatedly for three new tumor locations. Pain was the initial symptom in 16 of 25 schwannoma patients, and in 3 of 11 patients with meningiomas. Pain levels decreased in 8/19 patients. All but one patient with motor deficits remained clinically stable. No myelopathic signs were found. Single-session radiosurgery for benign spinal tumors in selected patients has proven to inhibit tumor progression within the observed period without signs of early toxicity. Radiosurgery offers an additional treatment option, if microsurgery is not feasible in cases of tumor recurrence, post-resection remnants, multiple lesions, or medical comorbidity.

Key words: Spinal; Meningioma; Schwannoma; Cyberknife; Stereotactic radiosurgery; Image guidance.

### Introduction

Primary spinal tumors account for 4% of all tumors affecting the central nervous system. They include intradural intramedullary (20%) and intradural extramedullary tumors (80%) (1). Two thirds of all spinal tumors are benign intradural extramedullary meningiomas (50%) or nerve sheath tumors (50%, schwannomas) (2). They may cause spinal cord or nerve root compression, which can result in pain, paresthesia, motor deficits, sphincter disturbances or myelopathy. The standard therapy for symptomatic benign spinal tumors is microsurgical resection. However, a surgical procedure may not always be favorable because of tumor location, medical impairment or in cases of tumor recurrence or remnants after microsurgery. Chemotherapy or immunotherapy seems to be of little effect for benign lesions (3).

M. Kufeld, M.D.<sup>1\*</sup>  
B. Wowra, M.D.<sup>1</sup>  
A. Muacevic, M.D.<sup>1</sup>  
Stefan Zausinger, M.D.<sup>2</sup>  
Jörg-Christian Tonn, M.D.<sup>2</sup>

<sup>1</sup>European Cyberknife Center Munich  
Grosshadern, Max-Lebsche-Platz 31,  
81377 Munich, Germany

<sup>2</sup>Department of Neurosurgery,  
Ludwig-Maximilians-University,  
Campus Grosshadern,  
Marchioninistrasse 15,  
81377 Munich, Germany

\*Corresponding author:  
M. Kufeld, M.D.  
Phone: +49-89-4523360  
Fax: +49-89-45233616  
E-mail: markus.kufeld@cyber-knife.net

Radiosurgery has proven effective and safe for the treatment of benign intracranial tumors such as meningiomas or schwannomas. Transferring radiosurgical principles from cranial to extracranial treatments was once technically limited, but the introduction of frameless radiosurgical devices made such treatments feasible. Initially implanted reference markers were necessary to guarantee precise and accurate spinal image guidance. The latest technical developments allow the tracking of spinal segments without fiducials, and thereby have enabled a completely non-invasive approach. Extensive testing and clinical analysis confirmed the sub-millimeter accuracy of the procedure (4, 5). Similar to cranial sites, this precision allows the treatment of tumors close to nervous structures along the spinal column with a single fraction, as long as the lesions do not exceed a certain size.

Here we report local response, clinical symptoms, and toxicity after radiosurgery for selected patients with spinal meningiomas or schwannomas.

### **Materials and Methods**

Since October 2005 a series of 36 patients with benign spinal meningiomas or schwannomas was selected for radiosurgery at a dedicated institution. An interdisciplinary tumor board at the Munich University Hospital, involving neurosurgeons, radiation oncologists and radiosurgery specialists, confirmed the indication for treatment.

In the cohort, which was analyzed here, only symptomatic spinal meningiomas or schwannomas have been treated primarily. Additionally, 67% of patients had undergone microsurgical resection as the standard procedure and tumor remnants, recurrences, or multiple lesions demanded further radiosurgical treatments. Five patients, who were clinically asymptomatic prior to the radiosurgical treatment, required further treatment because of growing tumor remnants or tumor recurrence, or showed multiple lesions in familiar schwannomatosis.

Medical history, previous treatments, histology and clinical symptoms were recorded. Pain was quantified utilizing the visual analogue scale (VAS). Local tumor response, clinical symptoms and adverse events were evaluated clinically and by radiographic MRI assessment every six months for the first year and then every 12 months during follow-up.

Post-treatment effects were classified as “stable” for unchanged tumor size with or without interstitial regression, “decreased” for shrinkage of at least 10% of tumor volume, and “progressive”, if the lesion grew more than 10% without signs of necrosis or interstitial regression in two consecutive MRI series. Adverse treatment effects were registered and graded

according to the common terminology criteria for adverse events (CTCAE v.3.0) (6).

Timing of clinical visits and data collection was supported by a customized electronic database (7).

All patients were treated in an outpatient setting with a single irradiation fraction utilizing the CyberKnife® system equipped with Xsight® Spine tracking software (Accuray Inc. Sunnyvale CA). The image-guided tracking system offers a non-invasive treatment procedure. Stereoscopic radiographs of the involved spine segment are taken before each beam and compared directly with previously generated digitally reconstructed radiographs (DRRs). The image contrast of the spinal bone is used for surface rendering and superimposition. The live images of the spinal column are attuned with the DRRs and the three-dimensional correction values are employed directly by the robot. Internal markers or implanted fiducials are not necessary.

For the calculation of digitally reconstructed radiographs (DRRs) as well as for treatment planning a / computed tomography (CT) scans with 1.25 mm slice thickness are conducted covering at least two spinal levels above and below the lesion. CT datasets are fused with magnetic resonance imaging (MRI) scans for target definition and delineation of risk structures such as the dural sac and nerve roots. No additional margins are added to the target. The dose is prescribed to the 70% isodose line, enclosing the target with at least 95% coverage. The dose prescription is standardized, but was adapted if necessary according to histology, tumor size, and dose to the spinal cord. Conformity index, coverage, homogeneity, V10 (volume of surrounding tissue receiving more than 10Gy) and V8 (volume of the delineated dural sac receiving more than 8Gy) are recorded as quality parameters. All treatment plans and dose-volume-histograms (DVH) are evaluated by a medical physicist as well as two specialized neurosurgeons.

### **Results**

During a period of four years (October 2005-October 2009) 36 patients with 39 spinal lesions were treated in 38 sessions (see Table I). Median follow-up was 18 months (min 6-max 50). The median age was 45 years (range 18-80 years), with 22 female and 14 male patients. For patients with multiple lesions and repeated treatments see Table II. The median target volume was 3.4 cm<sup>3</sup> (range 0.2-43.4 cm<sup>3</sup>).

Histological evaluation revealed 25 schwannomas and 11 meningiomas (WHO grade I). In eight patients without histological tumor confirmation the lesions were categorized radiographically as schwannomas, because of their typical intraforaminal configuration. In all other cases diagnosis was confirmed by previous surgery at the same site (23 cases) or

**Table I**  
Patient characteristics.

No. of patients	36
Female	22 (61%)
Male	14 (39%)
Age (yrs)	
Median	45
95% C.I.	40-54
Range	18-80
Volume of lesions (cm <sup>3</sup> )	
Median	3.4
95% C.I.	2.0-5.3
Mean	5.6
Range	0.2-43.4
Histology	
Schwannoma	25 (69%)
Meningioma (WHO grade I)	11 (31%)

another spinal level in five cases with multiple lesions. One patient suffered from neurofibromatosis type I and two had a confirmed neurofibromatosis type II. One patient had a hereditary schwannomatosis.

Spinal levels are displayed in Table III. Eighteen lesions were located intraspinally, 9 of these also intradurally; 21 lesions were located paraspinally or intraforaminally. The median prescription dose was 14Gy (95% C.I. 13.4-14Gy) with a minimum dose of 12Gy and a maximum dose of 15Gy (see Table IV). The median prescription dose was 13.5Gy (95% C.I. 13-14Gy) for schwannomas, and 14Gy (95% C.I. 13-15Gy) for meningiomas. The dose was prescribed to the 70% isodose line enclosing the target.

Initial clinical symptoms (pain, sensory, and motor deficits) are summarized in Table V. Nine patients were without symptoms before treatment. Two patients already showed myelopathic signs before treatment.

### Radiographic Outcome

After a median follow-up of 18 months (range 6-50 months) we did not see any local tumor progression. One patient with

**Table II**  
Tumor characteristics (n = 36).

Characteristics	Schwannoma 25 patients	Meningioma 11 patients
Singular lesion	18	10
Multiple lesions	7	1
No surgery	8	4
Surgery	17	7
Recurrence after surgery	4	4
Remnant after surgery	7	3
Surgery at other site	6	0

**Table III**

Spinal level of lesion (number of lesions = 39).

Level	No. of lesions (%)
Cervical	15 (39)
Thoracic	9 (23)
Lumbar	11 (28)
Sacrum	4 (10)

hereditary schwannomatosis required two additional radiosurgical treatments for three distant spinal tumors.

Seventeen patients (47%) had stable tumors, which showed specific imaging reactions after radiosurgery (Figure 1). This positive radiographic response was comprised of imaging changes such as reduced central contrast enhancement or a clear delineation of the lesion towards the surrounding tissue. In 19 patients (53%) tumor size was significantly reduced (over 10% of volume). Two patients developed a transient enlargement of their lesions, associated with changes in the interstitial structure and contrast enhancement that suggested a positive response. Both lesions were schwannomas that showed no further enlargement.

### Clinical Outcome

Four meningioma and five schwannoma patients were without initial symptoms. Pain as an initial symptom was common in schwannoma patients (16 of 25 with a median VAS score of 5) and less frequent in patients with meningiomas (3 of 11 with a median VAS score of 5). One patient with a schwannoma had the highest score (VAS 10) initially, which reduced to VAS 1 after treatment. She developed another painful schwannoma (VAS 8) and underwent radiosurgery again for this new lesion. Finally her pain syndrome reduced after the last treatment to VAS 2.

A reduction of the initial pain level could be achieved in 8 patients, 7 of the 16 schwannoma patients and 1 of the 3 patients with meningioma. One patient suffered from worsening of his symptoms (pain, sensory deficit) while a slight swelling of his schwannoma in the left foraminal canal at level C 3/4 was observed in the MRI six months after treatment.

One patient with a ventral intradural meningioma at level C 1 and initial gait disturbance developed a transient aggravation of her symptoms without radiographic signs of myelopathy. The disturbances improved after ten days of oral steroid medication. All other patients who presented with motor deficits remained stable, one improved. Ten of the 15 patients with sensory deficits remained stable. Four patients with a sensory deficit improved after the treatment (3 schwannomas, 1 meningioma). We did not see any newly developed myelopathic signs radiographically or clinically.

**Table IV**  
Average treatment parameters for 39 total lesions.

	Mean	Range	Median	95% C.I.
Prescription Dose (Gy)	13.8	12-15	14	13.4-14
Maximum Dose (Gy)	19.6	18.6-21.5	19.3	18.6-20.0
Minimum Dose (Gy)	10.9	6.2-14.8	11.4	10.5-12.0
Peripheral Isodose (%)	69.1	65-70	70	70-70
No. of beams/target	163	86-253	162	140-177
V8 dural sac (cm <sup>3</sup> )	0.22	0-1.22	0.16	0.03-0.2
V10 (cm <sup>3</sup> )	13.8	0.26-112.8	7.6	4.9-12.0

No significant difference between meningiomas and schwannomas.

None of the patients without initial symptoms developed new clinical deficits. In addition, we did not observe any irradiation side effects apart from mild nausea (grade I CTCAE v3.0) after treatment in three patients. No other toxic adverse effects have been noticed (grade II CTCAE v3.0 or higher). None of the patients had to undergo repeated microsurgery after radiosurgery. One 76-year-old female patient died 21 months after radiosurgery due to progressive lung cancer.

### Discussion

Only few reports on radiosurgery for benign spinal tumors have been published so far (8-13). To our knowledge, this is the first study analyzing the outcome of robotic radiosurgery for benign spinal meningiomas and schwannomas treated exclusively with a single-fraction scheme applying the non-invasive fiducial free setup.

The standard treatment of benign spinal lesions is microsurgical resection via laminectomy or recently minimally invasive operation techniques (14-17). The primary goal is a complete excision of the symptomatic tumor without compromising nervous structures. The secondary goal is a confirmation of the radiological diagnosis by histological

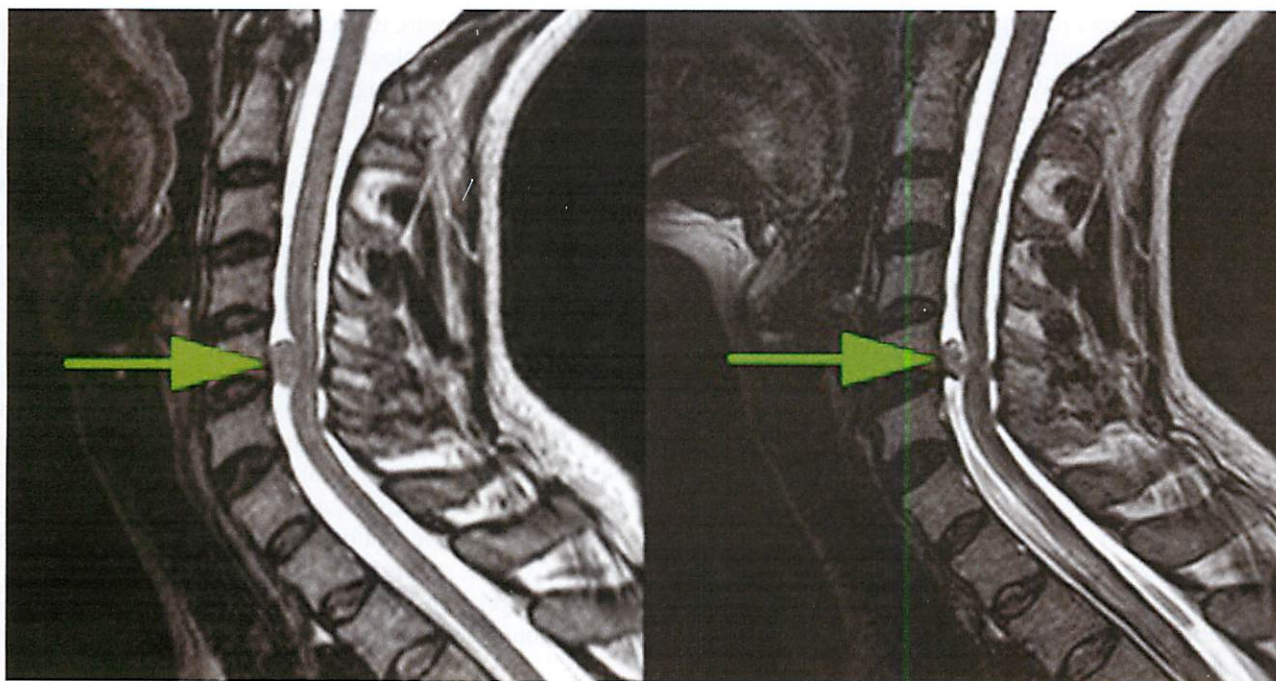
evaluation. Complete resection should be accomplished to favor a low recurrence rate (10, 18) and can be achieved in 97% of the primarily operated cases (19, 20). Tumor recurrence varies from 1.3% to 6.4% in a timeframe of one to 17 years (2, 21). Unlike primary meningiomas and schwannomas respecting tissue limits, recurrent tumors show a more infiltrative growths pattern, making a second surgical intervention more difficult (22). According to Solero *et al.*, only 45% of recurrent meningiomas can be removed completely (20). The altered anatomical configuration after open surgery, in combination with arachnoidal scarring, raises the surgical risk. Saraceni *et al.*, list further aspects precluding an adequate surgical management of spinal meningiomas like en plaque growth, inaccessible tumors, proximity to vital structures, and preexisting comorbidities (16). Here radiosurgery may offer an alternative treatment option for recurrent benign tumors or otherwise contrarious surgical cases.

Two thirds of our patients had undergone local tumor resection prior to the radiosurgical treatment. All lesions were confirmed as benign (WHO grade I). Eight patients presented with a recurrent tumor after surgery and required further treatment (23). In the other cases, tumor remnants after surgery, the operative risk because of comorbidities, reluctance

**Table V**  
Clinical outcome (VAS = visual analogue scale, RS = Radiosurgery).

		Schwannoma	Meningioma	Total
No pain		n = 11	n = 8	n = 19
Pain before RS		n = 16	n = 3	n = 19
VAS (Median)		5	5	5
Pain after RS		n = 16	n = 3	n = 19
VAS (Median)		2 (p < 0.02)	5	3
Sensory deficit before RS		10	5	15
	better	3	1	4
Sensory deficit after RS	stable	6	4	10
	worse	1		1
Motor deficit before RS		6	3	9
	better	1		1
Motor deficit after RS	stable	5	2	7
	worse		1	1
No initial symptoms		5	4	9





**Figure 1:** Sagittal T2 MRI demonstrating an intradural meningioma (arrows) at level C5 before (left) and 34 months after radiosurgery (right).

of patients towards open surgery or multiple tumor sites have been the reason for choosing radiosurgery as treatment option. In cases with multiple lesions, often associated with neurofibromatosis or schwannomatosis, a potent non-invasive treatment option is desirable. Otherwise these patients undergo frequent surgical procedures over time, with considerable impact on their quality of life (24). If the diagnosis is already ascertained by previous microsurgery or radiographical evaluation and supersedes another histological confirmation, these patients may be treated effectively by spinal radiosurgery. Also medically impaired patients with a high peri-operative risk profile, may benefit from radiosurgery in the first line after individual evaluation. In each case an interdisciplinary board integrating neurosurgeons and radiation oncologists specialized in radiosurgery should decide for the best treatment option.

The radiosurgical approach has proven to offer an effective and safe treatment option and is nowadays an established therapy for benign intracranial tumors (25-29). For malignant spinal tumors, extracranial radiosurgery is currently developing and successively replaces surgery or conventional radiation therapy in selected cases (30, 31).

The expansion of the radiosurgical principle to the treatment of spinal lesions was particularly enabled after the implementation of the Xsight Spine tracking system, which allows a non-invasive tracking and treatment procedure (4, 32-36). Therefore the implantation of markers used for tracking is no longer necessary. During treatment patients are lying

freely on the treatment couch without any rigid fixation or additional tracking device. Medically impaired or elderly patients appreciate the comfortable preparation and treatment procedure. To account for patient movement and thus inaccuracy during the treatment, we analyzed the correction logs of the couch system. Patient motion occurring between position imaging acquisitions can be estimated from the correction values. The mean vector of inaccuracy, drawn from 260 spinal treatments, was 0.6 mm, with a maximum of 1 mm inaccuracy between two images in the worst case (37). These small error values confirm the precision of the tracking system and accuracy of the treatment. The effective dose attributed to the imaging during treatment is dependent on the entrance dose and even more the body location and required number of images. It is comparable to a diagnostic CT scan of the treated body region (38).

For accurate spinal tracking as well as the delineation of target and risk structures, high-resolution radiographs are necessary, especially if small lesions in close contact with the spinal cord have to be identified. We propose 1 millimeter slices of T1 contrast-enhanced MRI series, which are fused with the planning CT slices.

In addition to its use in treatment planning, high resolution MR imaging is mandatory for the radiographic outcome evaluation. In the follow-up of radiosurgically treated benign lesions, only little radiographic changes are expected, making the correct evaluation challenging (39). The response of spinal lesions to radiosurgery does not seem to differ from



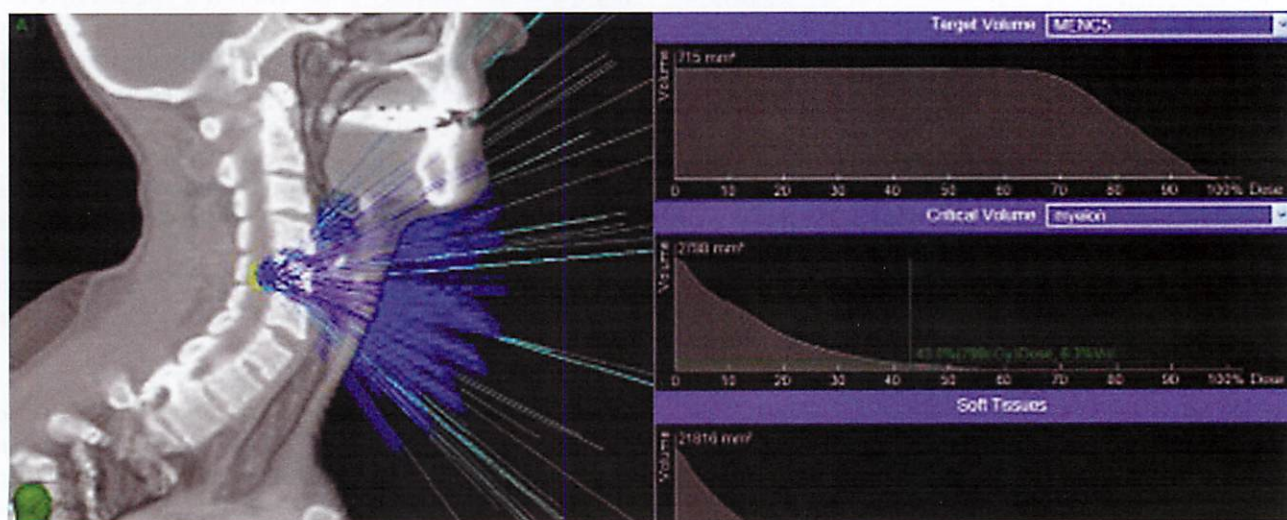
intracranial benign tumors such as meningiomas or vestibular schwannomas (40). A significant reduction in size (over 10% in volume) was seen in 53% of our cases. This corresponds well with the findings of other authors, although our follow-up is relatively short with a median of 18 months (41, 42). However, additional criteria apart from tumor volume should be used to evaluate the response to radiosurgical treatment, especially for cases without noticeable tumor shrinkage. Criteria we use are loosening of the internal tumor structure, reduction of central contrast enhancement, and attenuated delineation of the target towards surrounding tissue. These radiographic findings are signs for a positive response of the lesion, even if a transient enlargement may occur because of tumor swelling. Dedicated specialists, who are experienced in evaluating post-radiosurgical imaging, should provide the radiographic outcome evaluation.

Since benign tumors tend to react slowly to radiosurgery and late recurrences may occur after several years, the current study is limited by its relatively short follow-up. However, some conclusions regarding efficacy and safety can be made. We observed no local tumor recurrence in our selection of patients. The efficacy of the treatment is comparable to outcomes described by other authors (8, 43). The absence of severe adverse events or significant deterioration of clinical or radiological findings, especially myelopathic signs, supports claims about the safety of the treatment. Even with the relatively short follow-up myelopathic signs would be expected in this period, as reported by Gibbs *et al.*, they encountered six myelopathies approximately six months after image-guided spinal radiosurgery in a group of more than 1000 treated patients (44). Since the follow up of our patients is mostly longer than six months, we do not expect to see any

severe adverse events in the following years. Nevertheless, neurological or radiological deteriorations have to be cautiously followed. Although no significant predictive factors for myelon toxicity have been identified by Gibbs *et al.*, they suggest keeping the volume of spinal cord exposed to more than 8 Gy below 1 cm<sup>3</sup> (44). A more detailed analysis by Shagal *et al.*, could identify constraints regarding maximum point doses for the spinal cord with regard to the fractionation scheme (45). In single fraction treatments this value should be kept below 10 Gy to prevent radiation induced myelopathy. However, with regard to our concept of contouring the dural sac as the organ at risk, the maximum point dose seemed not to be a reasonable value and therefore we concentrated on the volume based concept of the 8-Gray volume. In our data the median volume of the dural sac receiving more than 8 Gy equals to a value of 0.2 cm<sup>3</sup> and a maximum value of 1.2 cm<sup>3</sup> (Figure 2). Since we contour the dural sac and not only the myelon as a risk structure in our treatment planning, an additional safety margin is given towards the nervous tissue. Thus, we feel confident that our treatment approach is a safe one.

### Conclusion

Single-session robotic radiosurgery for spinal meningiomas and schwannomas has proven to be a safe, non-invasive treatment option, inhibiting tumor progression within the observation period in selected patients. Microsurgical tumor resection remains the primary therapy of choice for benign spinal lesions. However, radiosurgery seems to be an effective tool for patients, who are not suitable for open surgery, as well as for patients with multiple lesions, recurrences, or tumor remnants after microsurgery.



**Figure 2:** Beam distribution (left) and dose-volume-histogram of target (upper right) and myelon (lower right). The volume of the myelon receiving more than 8 Gy corresponds to 0.17 cm<sup>3</sup>. Prescription dose 13 Gy prescribed to the 70% isodose.

# Disclosure

The authors report no conflict of interest concerning the materials or methods used in this study or the findings specified in this paper.

# Acknowledgements

The authors thank Daniela Ellmann for data work and David Schaal for editing the english version.

# References

- Grimm, S., Chamberlain, M. C. Adult primary spinal cord tumors. *Expert Rev Neurother* 9(10), 1487-1495 (2009).
- Gottfried, O. N., Gluf, W., Quinones-Hinojosa, A., Kan, P., Schmidt, M. H. Spinal meningiomas: surgical management and outcome. *Neurosurg Focus* 14(6), e2 (2003).
- Sioka, C., Kyritsis, A. P. Chemotherapy, hormonal therapy, and immunotherapy for recurrent meningiomas. *J Neurooncol* 92(1), 1-6 (2009).
- Muacevic, A., Staehler, M., Drexler, C., Wowra, B., Reiser, M., Tonn, J. C. Technical description, phantom accuracy, and clinical feasibility for fiducial-free frameless real-time image-guided spinal radiosurgery. *J Neurosurg Spine* 5(4), 303-312 (2006).
- Ho, A. K., Fu, D., Cotrutz, C., Hancock, S. L., Chang, S. D., Gibbs, I. C., Maurer, C. R. J., Adler, J. R. J. A study of the accuracy of cyberknife spinal radiosurgery using skeletal structure tracking. *Neurosurgery* 60(2), Suppl. 1, ONS147-56; discussion ONS156 (2007).
- Trotti, A., Colevas, A. D., Setser, A., Rusch, V., Jaques, D., Budach, V., Langer, C., Murphy, B., Cumberlin, R., Coleman, C. N., Rubin, P. CTCAE v3.0: development of a comprehensive grading system for the adverse effects of cancer treatment. *Semin Radiat Oncol* 13(3), 176-181 (2003).
- Kufeld, M., Fürweger, C., Drexler, C., Wowra, B., Muacevic, A. Implementation of a Medical Database System for a Radiosurgery Center. [www.peermed.com](http://www.peermed.com) (2009).
- Dodd, R. L., Ryu, M. R., Kamnerdsupaphon, P., Gibbs, I. C., Chang, S. D. J., Adler, J. R. J. CyberKnife radiosurgery for benign intradural extramedullary spinal tumors. *Neurosurgery* 58(4), 674-85; discussion 674-85 (2006).
- Gerszten, P. C., Burton, S. A., Ozhasoglu, C., McCue, K. J., Quinn, A. E. Radiosurgery for benign intradural spinal tumors. *Neurosurgery* 62(4), 887-95; discussion 895-6 (2008).
- Gezen, F., Kahraman, S., Canakci, Z., Beduk, A. Review of 36 cases of spinal cord meningioma. *Spine (Phila Pa 1976)* 25(6), 727-731 (2000).
- Selch, M. T., Lin, K., Agazaryan, N., Tenn, S., Gorgulho, A., Demarco, J. J., Desalles, A. A. Initial clinical experience with image-guided linear accelerator-based spinal radiosurgery for treatment of benign nerve sheath tumors. *Surg Neurol* 72(6), 668-674 (2009).
- Sahgal, A., Chou, D., Ames, C., Ma, L., Lamborn, K., Huang, K., Chuang, C., Aiken, A., Petti, P., Weinstein, P., Larson, D. Image-guided robotic stereotactic body radiotherapy for benign spinal tumors: the University of California San Francisco preliminary experience. *Technol Cancer Res Treat* 6(6), 595-604 (2007).
- Gerszten, P. C., Ozhasoglu, C., Burton, S. A., Vogel, W. J., Atkins, B. A., Kalnicki, S., Welch, W. C. CyberKnife frameless single-fraction stereotactic radiosurgery for benign tumors of the spine. *Neurosurg Focus* 14(5), e16 (2003).
- Roux, F. X., Nataf, F., Pinaudeau, M., Borne, G., Devaux, B., Meder, J. F. Intraspinal meningiomas: review of 54 cases with discussion of poor prognosis factors and modern therapeutic management. *Surg Neurol* 46(5), 458-63; discussion 463-4 (1996).
- Parsa, A. T., Lee, J., Parney, I. F., Weinstein, P., McCormick, P. C., Ames, C. Spinal cord and intradural-extramedullary spinal tumors: current best care practices and strategies. *J Neurooncol* 69(1-3), 291-318 (2004).
- Saraceni, C., Harrop, J. S. Spinal meningioma: chronicles of contemporary neurosurgical diagnosis and management. *Clin Neurol Neurosurg* 111(3), 221-226 (2009).
- Tredway, T. L., Santiago, P., Hrubes, M. R., Song, J. K., Christie, S. D., Fessler, R. G. Minimally invasive resection of intradural-extramedullary spinal neoplasms. *Neurosurgery* 58(Suppl. 1), ONS52-8; discussion ONS52-8 (2006).
- McCormick, P. C., Post, K. D., Stein, B. M. Intradural extramedullary tumors in adults. *Neurosurg Clin N Am* 1(3), 591-608 (1990).
- Yoon, S. H., Chung, C. K., Jahng, T. A. Surgical outcome of spinal canal meningiomas. *J Korean Neurosurg Soc* 42(4), 300-304 (2007).
- Solero, C. L., Fornari, M., Giombini, S., Lasio, G., Oliveri, G., Cimino, C., Pluchino, F. Spinal meningiomas: review of 174 operated cases. *Neurosurgery* 25(2), 153-160 (1989).
- Mirimanoff, R. O., Dosoretz, D. E., Linggood, R. M., Ojemann, R. G., Martuza, R. L. Meningioma: analysis of recurrence and progression following neurosurgical resection. *J Neurosurg* 62(1), 18-24 (1985).
- Klekamp, J., Samii, M. Surgical results for spinal meningiomas. *Surg Neurol* 52(6), 552-562 (1999).
- Radner, H., Blumcke, I., Reifenberger, G., Wiestler, O. D. [The new WHO classification of tumors of the nervous system 2000. Pathology and genetics]. *Pathologe* 23(4), 260-283 (2002).
- Gagnon, G. J., Nasr, N. M., Liao, J. J., Molzahn, I., Marsh, D., McRae, D., Henderson, F. C. S. Treatment of spinal tumors using cyberknife fractionated stereotactic radiosurgery: pain and quality-of-life assessment after treatment in 200 patients. *Neurosurgery* 64(2), 297-306; discussion 306-7 (2009).
- Pollock, B. E. Stereotactic radiosurgery for intracranial meningiomas: indications and results. *Neurosurg Focus* 14(5), e4 (2003).
- Pollock, B. E., Stafford, S. L., Utter, A., Giannini, C., Schreiner, S. A. Stereotactic radiosurgery provides equivalent tumor control to Simpson Grade I resection for patients with small- to medium-size meningiomas. *Int J Radiat Oncol Biol Phys* 55(4), 1000-1005 (2003).
- Lee, J. Y., Kondziolka, D., Flickinger, J. C., Lunsford, L. D. Radiosurgery for intracranial meningiomas. *Prog Neurol Surg* 20, 142-149 (2007).
- Colombo, F., Casentini, L., Cavedon, C., Scalchi, P., Cora, S., Francescon, P. Cyberknife radiosurgery for benign meningiomas: short-term results in 199 patients. *Neurosurgery* 64(Suppl. 2), A7-13 (2009).
- Pollock, B. E. Stereotactic radiosurgery of benign intracranial tumors. *J Neurooncol* 92(3), 337-343 (2009).
- Rock, J. P., Ryu, S., Yin, F. F., Schreiber, F., Abdulhak, M. The evolving role of stereotactic radiosurgery and stereotactic radiation therapy for patients with spine tumors. *J Neurooncol* 69(1-3), 319-334 (2004).
- Wowra, B., Zausinger, S., Drexler, C., Kufeld, M., Muacevic, A., Staehler, M., Tonn, J. C. CyberKnife radiosurgery for malignant spinal tumors: characterization of well-suited patients. *Spine (Phila Pa 1976)* 33(26), 2929-2934 (2008).
- Gerszten, P. C., Ozhasoglu, C., Burton, S. A., Vogel, W., Atkins, B., Kalnicki, S., Welch, W. C. Evaluation of CyberKnife frameless real-time image-guided stereotactic radiosurgery for spinal lesions. *Stereotact Funct Neurosurg* 81(1-4), 84-89 (2003).
- Gerszten, P. C., Ozhasoglu, C., Burton, S. A., Kalnicki, S., Welch, W. C. Feasibility of frameless single-fraction stereotactic radiosurgery for spinal lesions. *Neurosurg Focus* 13(4), e2 (2002).
- Bhatnagar, A. K., Gerszten, P. C., Ozhasoglu, C., Vogel, W. J., Kalnicki, S., Welch, W. C., Burton, S. A. CyberKnife Frameless Radiosurgery for the treatment of extracranial benign tumors. *Technol Cancer Res Treat* 4(5), 571-576 (2005).
- Gerszten, P. C., Burton, S. A., Ozhasoglu, C. CyberKnife radiosurgery for spinal neoplasms. *Prog Neurol Surg* 20, 340-358 (2007).

36. Avanzo, M., Romanelli, P. Spinal radiosurgery: technology and clinical outcomes. *Neurosurg Rev* 32(1), 1-12; discussion 12-3 (2009).
37. Furweiger, C., Drexler, C., Kufeld, M., Muacevic, A., Wowra, B., Schlaefer, A. Patient Motion and Targeting Accuracy in Robotic Spinal Radiosurgery: 260 Single-Fraction Fiducial-Free Cases. *Int J Radiat Oncol Biol Phys* 78(3), 937-945 (2010).
38. Murphy, M. J., Balter, J., Balter, S., BenComo, J. A. J., Das, I. J., Jiang, S. B., Ma, C. M., Olivera, G. H., Rodebaugh, R. F., Ruchala, K. J., Shirato, H., Yin, F. F. The management of imaging dose during image-guided radiotherapy: report of the AAPM Task Group 75. *Med Phys* 34(10), 4041-4063 (2007).
39. Henzel, M., Gross, M. W., Hamm, K., Surber, G., Kleinert, G., Failing, T., Strassmann, G., Engenhart-Cabillic, R. Significant tumor volume reduction of meningiomas after stereotactic radiotherapy: results of a prospective multicenter study. *Neurosurgery* 59(6), 1188-94; discussion 1194 (2006).
40. Meijer, O. W., Weijmans, E. J., Knol, D. L., Slotman, B. J., Barkhof, F., Vandertop, W. P., Castelijns, J. A. Tumor-volume changes after radiosurgery for vestibular schwannoma: implications for follow-up MR imaging protocol. *AJNR Am J Neuroradiol* 29(5), 906-910 (2008).
41. Murovic, J. A., Gibbs, I. C., Chang, S. D., Mobley, B. C., Park, J., Adler, J. R. J. Foraminal nerve sheath tumors: intermediate follow-up after cyberknife radiosurgery. *Neurosurgery* 64(Suppl. 2), A33-43 (2009).
42. Ryu, S. I., Chang, S. D., Kim, D. H., Murphy, M. J., Le, Q. T., Martin, D. P., Adler, J. R. J. Image-guided hypo-fractionated stereotactic radiosurgery to spinal lesions. *Neurosurgery* 49(4), 838-846 (2001).
43. Saraceni, C., Ashman, J. B., Harrop, J. S. Extracranial radiosurgery—applications in the management of benign intradural spinal neoplasms. *Neurosurg Rev* 32(2), 133-40; discussion 140-1 (2009).
44. Gibbs, I. C., Patil, C., Gerszten, P. C., Adler, J. R. J., Burton, S. A. Delayed radiation-induced myelopathy after spinal radiosurgery. *Neurosurgery* 64(Suppl. 2), A67-72 (2009).
45. Sahgal, A., Ma, L., Gibbs, I., Gerszten, P. C., Ryu, S., Soltys, S., Weinberg, V., Wong, S., Chang, E., Fowler, J., Larson, D. A. Spinal cord tolerance for stereotactic body radiotherapy. *Int J Radiat Oncol Biol Phys* 77, 548-553 (2010).

Received: August 15, 2011; Revised: September 18, 2011;

Accepted: October 25, 2011